Tissues, Pathology, and Diagnostic Microscopy

LS.2.P077
The effects of Subepineurial Hyaluronic Acid injection on Nerve Regeneration.

A. Altinkaya[1], G. Cebi[2], G. Tanriverdi[3], O. Cetinkale[2], F. Alkan[3]

[1]Kahramanmaras Necip Fazil City Hospital., Plastic and Recontructive and Aesthetic Surgery Clinic, Kahramanmaras, Turkey
[2]Istanbul University, Cerrahpasa Medical Faculty, Plastic and Recontructive and Aesthetic Surgery Dept., Istanbul, Turkey
[3]Istanbul University, Cerrahpasa Medical Faculty, Histology and Embryology Dept., Istanbul, Turkey

altualtinkaya@yahoo.com
Key words: hyaluronic acid, nerve regeneration, nerve healing.

Establishing epineural integrity is very important for nerve healing. Reporting usage of substances considered that had positive effect on the nerve healing in experimentally induced nerve defect models is increasing. In this study, effects of subepineural injection of hyaluronic acid in sciatic nerve defect model that was created while maintinig the integrity of epineurium, was investigated.

Thirty - two Sprague -Dawley type female rats weighing between 200 – 250 gram were randomly divided into four groups of eigth rats each. Control Group :The right sciatic nerve was dissected from the sciatic notch to the distally and no additional surgery was performed. Experimental Group 1: The right sciatic nevre was transected in the middle part then repaired end to end with epineural sutures. Experimental Group 2: One centimeter defect was created while preserving epinerium then defect was repaired by end to end suturation of preserved epineurium. Experimental Group 3: In addition to surgical procedure was carried out in experimental group 2, subepineural injection of hyaluronic acid was performed.

In 0, 2, 4, 8 and 12th weeks walking track analysis were performed and sciatic functional index was calculated according to Bain - Mackinnon – Hunter formula. Sciatic nerve samples taken from animals were examined histologically in 12th week and average number of myelinated nerve fibers were calculated for each group.

In the end of the functional and histological examinations, healing in hyaluronic acid applied group (Experimental Group 3) is much better than no application + nerve defect only group (Experimental Group 2) and were found almost the same level with epineural repair group (Experimental Group 1) (Figure 1). As a result hyaluronic acid application enhances nerve regeneration.

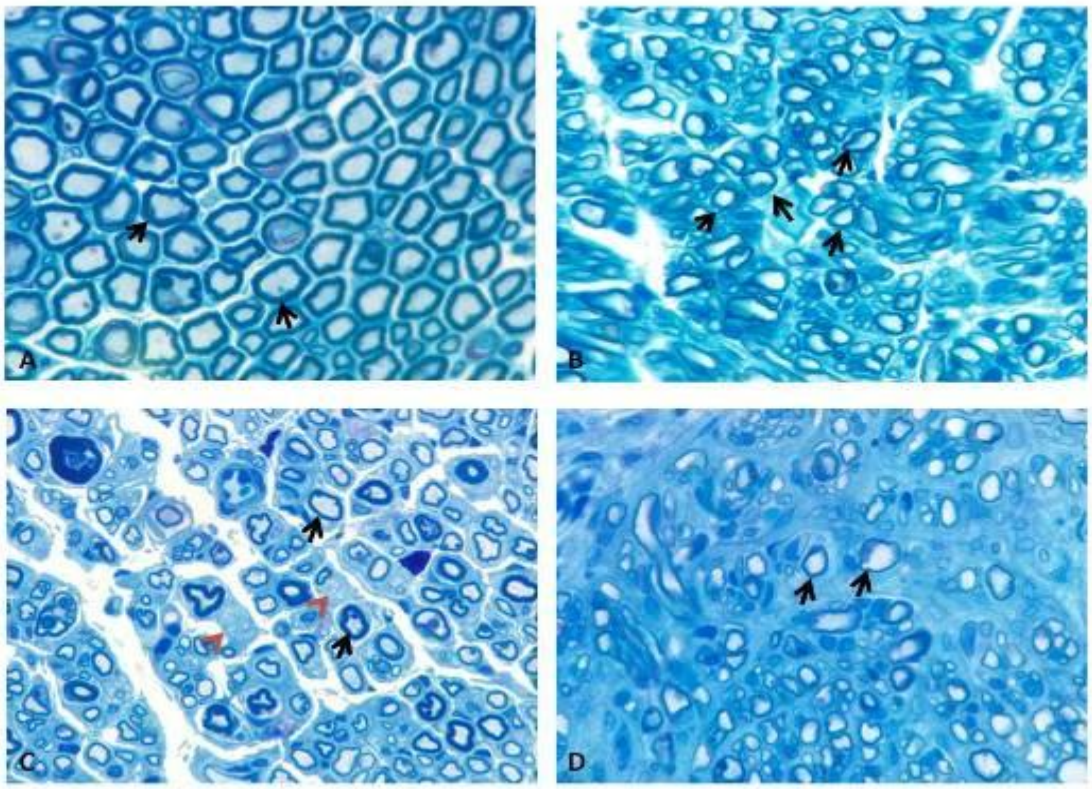

Figure 1
a.) Control Group: Myelinated nerve fibers (black arrow) Toluidin Blue x100.
b.) Experimental Group 1: Lots of Myelinated nerve fibers with different diamater (black arrow) Toluidin Blue x100.
c.) Experimental Group 2 : Lots of Myelinated nerve fibers with different diamater and also degeneratif and fibrotic areas can be seen (red arrows) Toluidin Blue x100.
d.) Experimental Group 3: Myelinated nerve fibers with different diamater were seen. Toluidin Blue x100.